

Ischaemic stroke as a presenting feature of ChAdOx1 nCoV-19 vaccine-induced immune thrombotic thrombocytopenia

A syndrome of vaccine-induced immune thrombotic thrombocytopenia (VITT) has recently been reported following the ChAdOx1 nCoV-19 (Oxford–AstraZeneca) recombinant adenoviral vector vaccine encoding the spike glycoprotein of SARS-CoV-2.^{1–4} Previously described patients developed thrombosis, mainly affecting cerebral venous sinuses, with thrombocytopenia and antibodies to platelet factor 4 (PF4), but the characteristics of VITT with arterial thrombosis have not previously been described. Here, we report three patients with VITT who presented with ischaemic stroke.

Patient 1, a 35-year-old Asian woman, developed episodic right temporal and periorbital headache 6 days after receiving the ChAdOx1 nCoV-19 vaccine. Five days later, she awoke with left face, arm and leg weakness, right gaze preference and drowsiness. Non-contrast CT and CT angiography (CTA) revealed occlusion of the right middle cerebral artery (MCA) distal M1 segment with extensive ischaemia and haemorrhagic transformation (**figure 1A–C**). Subsequent imaging revealed right portal vein thrombosis. The platelet count was $64 \times 10^9/L$ (reference range $150–400 \times 10^9/L$); D-dimer was raised at $11\,220 \mu g/L$ (reference range $0–550$); and the Asserachrom HPIA IgG assay for anti-PF4 antibodies was positive (76.1%). The patient underwent urgent decompressive hemicraniectomy (**figure 1D**). The platelet count increased after intravenous immune globulin and plasmapheresis. She received

anticoagulation with intermediate dose fondaparinux. Fourteen days after presentation, her conscious level suddenly dropped; CT head showed extensive haemorrhagic transformation of the left MCA infarct with mass effect and herniation of the brain through the decompressive hemicraniectomy. Brainstem death was subsequently confirmed.

Patient 2, a 37-year-old White female, presented 12 days after receiving the ChAdOx1 nCoV-19 vaccine with diffuse headache, left visual field loss, confusion and left arm weakness. CTA showed occlusion of both internal carotid arteries (**figure 1E**) and left transverse sinus thrombosis (**figure 1F**); diffusion-weighted MRI showed bilateral acute infarcts in a borderzone distribution (**figure 1G,H**). Subsequent imaging confirmed pulmonary embolism and thromboses of the left transverse and sigmoid sinuses, left jugular, right hepatic and both iliac veins.

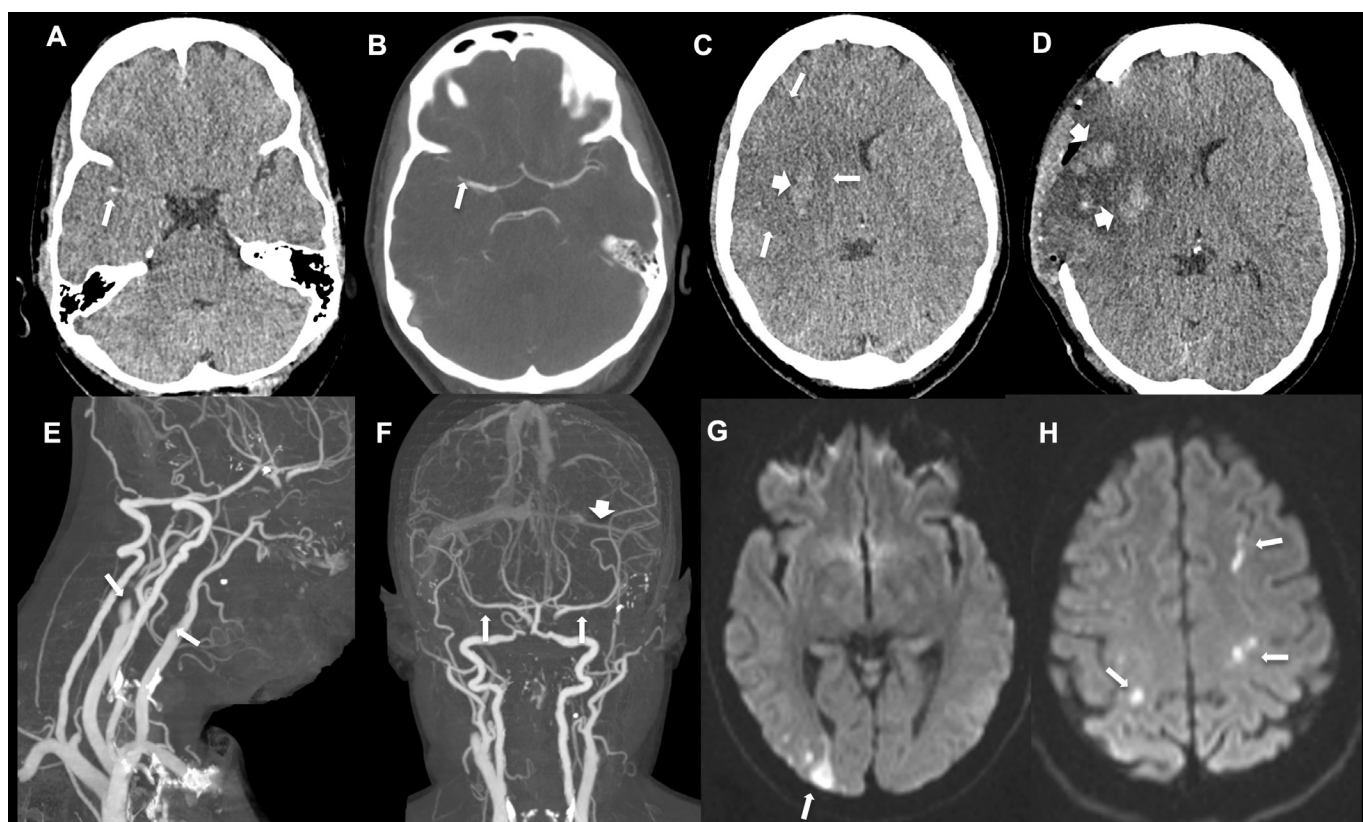


Figure 1 Patient 1: (A–D) non-enhanced CT (A) shows hyperdense clot in the distal right M1 segment (arrow), which corresponds to site of the occlusion demonstrated on the CT angiogram (B, arrow). The non-enhanced CT at the level of the basal ganglia (C) shows a large acute right middle cerebral artery infarct with loss of grey–white matter differentiation (arrows) and early haemorrhagic transformation (short arrow). A non-enhanced CT following emergency craniectomy (D) demonstrates swelling of the right hemisphere and extension of the haemorrhagic transformation (short arrows). Patient 2: (E–H) the extracranial CT angiogram (E) shows occlusion of both internal carotid arteries (arrows), the right being occluded from its postbulbous portion and the left at its origin. The intracranial CT angiography (F) demonstrates patent middle cerebral arteries bilaterally (arrows), which fill via collaterals predominantly from the posterior communicating arteries. There is also a lack of filling of the mid-portions and distal portions of the left transverse sinus (short arrow), suspicious of a thrombosis, later confirmed with a dedicated CT venogram. Magnetic resonance diffusion-weighted images (G,H) reveal several acute infarcts in the right occipital lobe (arrow in G) and centrum semiovale bilaterally (arrows in H), corresponding to cortical as well as deep and superficial arterial borderzone territories.

The platelet count was $9 \times 10^9/L$; D-dimer was raised at $34\,000\,\mu g/L$; and the anti-PF4 antibody assay was positive (99.7%). The platelet count increased following treatment with intravenous immune globulin, two intravenous pulses of methylprednisolone and plasmapheresis; the patient then received fondaparinux and improved clinically.

Patient 3, a 43-year-old Asian male, presented 21 days after the ChAdOx1 nCoV-19 vaccine with dysphasia. CT and magnetic resonance (MR) showed an acute left frontal and insular infarct corresponding to the anterior cortical territory of the left MCA, with a small volume of haemorrhagic transformation within the infarct. MR and CT venography showed no evidence of cerebral venous sinus thrombosis. The platelet count was $48 \times 10^9/L$; D-dimer was raised at $24\,000\,\mu g/L$; and the anti-PF4 antibody assay was positive. He was treated with platelet transfusion, intravenous immune globulin and fondaparinux and remains clinically stable.

Our observations suggest that, in addition to venous thrombosis, the neurological spectrum of VITT can include arterial occlusion. Young patients presenting with ischaemic stroke after receiving the ChAdOx1 nCoV-19 vaccine should urgently be evaluated for VITT with laboratory tests (including platelet count, D-dimers, fibrinogen and anti-PF4 antibodies) and assessment for co-existing venous thromboses; they should be managed by a multidisciplinary team (haematology,

neurology, stroke, neurosurgery and neuroradiology) for rapid access to treatments including intravenous immune globulin, methylprednisolone, plasmapheresis and non-heparin anticoagulants, for example fondaparinux, argatroban, or direct oral anticoagulants. Endovascular therapy or decompressive hemicraniectomy may also be indicated in carefully selected patients.^{1 3 5}

Talal Al-Mayhany,¹ Sadia Saber,¹ Matthew J Stubbs,² Nicholas A Losseff,¹ Richard J Perry^{1,3}, Robert J Simister,^{1,3} David Gull,⁴ Hans Rolf Jäger,^{3,5} Marie A Scully,² David J Werring^{1,3}

¹Comprehensive Stroke Service, National Hospital for Neurology and Neurosurgery, University College London Hospitals NHS Foundation Trust, London, UK

²Department of Haematology, University College

London Hospitals NHS Foundation Trust, London, UK

³Stroke Research Centre, UCL Queen Square Institute of Neurology, London, UK

⁴Stroke Service, Sandwell and West Birmingham Hospitals NHS Trust, Birmingham, UK

⁵Academic Neuroradiological Unit, UCL Queen Square Institute of Neurology, London, UK

Correspondence to Professor David J Werring,

Stroke Research Centre, UCL Queen Square Institute of

Neurology, London, UK; d.werring@ucl.ac.uk

Contributors DJW and MAS had the idea for the paper. TA-M prepared the first draft with DJW and SS. HRJ prepared the draft figures. MJS, NAL, RJP, RS and DG were involved in the clinical care of the patients. All authors critically reviewed the manuscript for intellectual content.

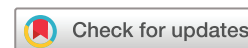Funding The authors have not declared a specific grant for this research from any funding agency in the public, commercial or not-for-profit sectors.

Competing interests None declared.

Patient consent for publication Not required.

Provenance and peer review Not commissioned; internally peer reviewed.

© Author(s) (or their employer(s)) 2021. No commercial re-use. See rights and permissions. Published by BMJ.



To cite Al-Mayhany T, Saber S, Stubbs MJ, et al. *J Neurol Neurosurg Psychiatry* Epub ahead of print: [please include Day Month Year]. doi:10.1136/jnnp-2021-326984

Received 27 April 2021

Accepted 28 April 2021

J Neurol Neurosurg Psychiatry 2021;0:1–2.

doi:10.1136/jnnp-2021-326984

ORCID iDs

Richard J Perry <http://orcid.org/0000-0002-4536-9018>

David J Werring <http://orcid.org/0000-0003-2074-1861>

REFERENCES

- 1 Scully M, Singh D, Lown R, et al. Pathologic antibodies to platelet factor 4 after ChAdOx1 nCoV-19 vaccination. *N Engl J Med* 2021. doi:10.1056/NEJMoa2105385. [Epub ahead of print: 16 04 2021].
- 2 Greinacher A, Thiele T, Warkentin TE, et al. Thrombotic thrombocytopenia after ChAdOx1 nCoV-19 vaccination. *N Engl J Med* 2021. doi:10.1056/NEJMoa2104840. [Epub ahead of print: 09 Apr 2021].
- 3 Schultz NH, Sørvoll IH, Michelsen AE, et al. Thrombosis and thrombocytopenia after ChAdOx1 nCoV-19 vaccination. *N Engl J Med* 2021. doi:10.1056/NEJMoa2104882. [Epub ahead of print: 09 Apr 2021].
- 4 Cines DB, Bussell JB. SARS-CoV-2 vaccine-induced immune thrombotic thrombocytopenia. *N Engl J Med* 2021. doi:10.1056/NEJMe2106315. [Epub ahead of print: 16 Apr 2021].
- 5 Oldenburg J, Klamroth R, Langer F, et al. Diagnosis and management of vaccine-related thrombosis following AstraZeneca COVID-19 vaccination: guidance statement from the GTH. *Hamostaseologie* 2021. doi:10.1055/a-1469-7481. [Epub ahead of print: 01 Apr 2021].