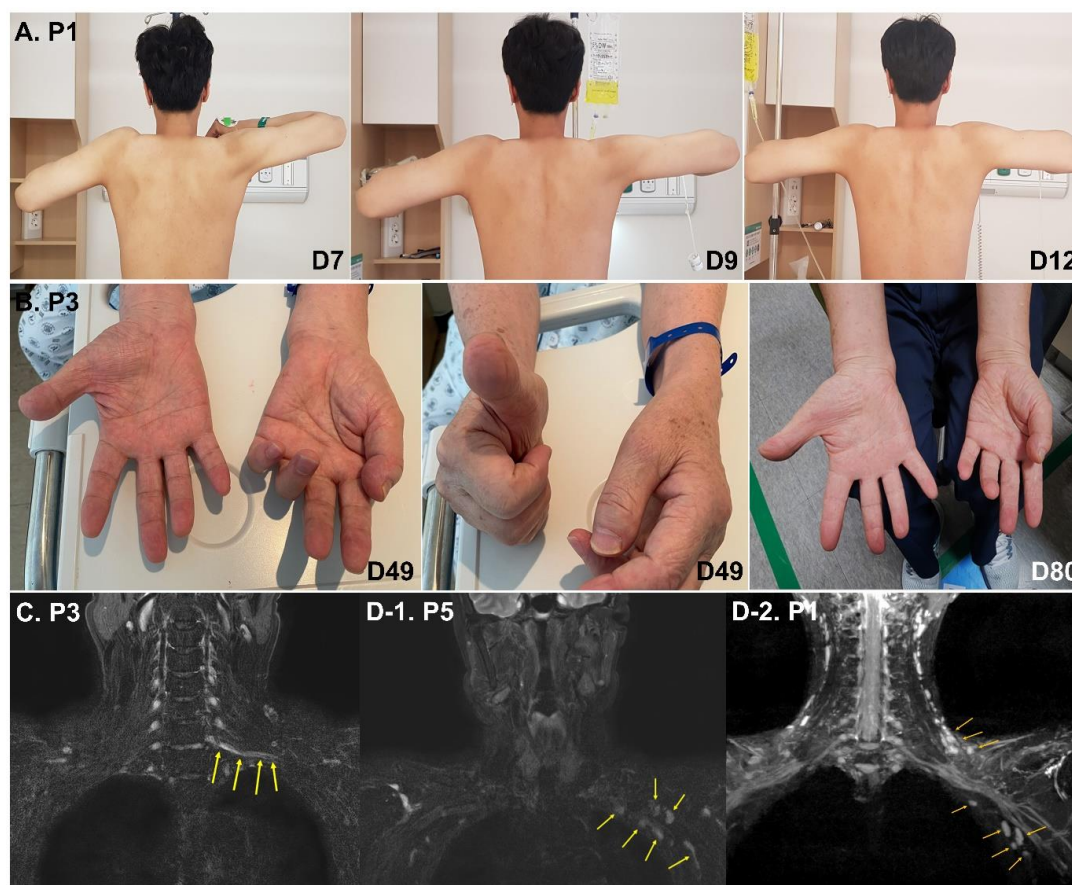


1 **Supplementary information**

2 **Supplementary Figure.** Illustrations of the clinical course and magnetic resonance image of
3 the brachial plexus in two representative cases with Parsonage-Turner syndrome post-
4 COVID-19 vaccination. Patient 1 (panel A) presented with moderate weakness in the
5 shoulder abduction (seven days from onset) which rapidly improved over the next five days
6 with the administration of intravenous methylprednisolone. Patient 3 (panel B) had severe
7 weakness of the left hand (49 days from onset, left and middle panels) and left with residual
8 deficits despite oral prednisolone treatment (right). Panel C shows the prominent thickening
9 and signal changes in the inferior trunk of the brachial plexus in patient 3. Ipsilateral
10 prominence of axillary and cervical lymph nodes was noted in four among six patients who
11 underwent MRI evaluation. Representative examples of patient 5 and patient 1 are shown (D-
12 1 and D-2, respectively).

13



14

1

2 **Supplementary Table. Summary of previous case reports of PTS post COVID-19**
 3 **vaccination.**

4

Authors	Journal, Year	Number of cases	Ipsilateral case	Vaccine
Queler SC, et al.	Radiology, 2021	2	1	Pfizer-BioNTech (1), Moderna (1)
Koh JS, et al.	QJM, 2021	3	2	Pfizer-BioNTech (2), mRNA-1273 (1)
Diaz-Segarra N, et al.	PM R, 2021	1	0	Pfizer-BioNTech
Mahajan S, et al.	Muscle Nerve, 2021	1	1	Pfizer-BioNTech
Vitturi BK, et al.	J Medical Case Rep, 2021	1	1	AstraZeneca
Nawaz SB & Raigam WA	EJMHS, 2022	1	1	mRNA (exact type was not specified)
Sharma A & Gupta A	Cureus, 2022	1	1	AstraZeneca

5